

Comprehensive Management of the Diabetic Foot

Collin E. Pehde, DPM, FACFAS
Assistant Professor
Des Moines University
College of Podiatric Medicine and Surgery
DMU Foot and Ankle Clinic



Iowa Affiliate WOCN Society
Fall Conference
September 13, 2019



1

Lecture Objectives

- Understand the comprehensive care approach to the Diabetic Foot
- Understand the orthoplastics approach to treat diabetic foot ulcers
- Understand treatment principles for treating foot and ankle Charcot deformity.

2

Comprehensive Management of The Diabetic Foot

- Maintenance Foot Care
- Wound Care
- Limb Salvage
 - Orthoplastics



3

Dreaded Complications of Diabetes

The Big Three

- Blindness
- Kidney Failure
- **Foot and Leg Amputation**

4


The Bad News

- Amputations usually start out as preventable, easy to treat problems
 - Calluses, ingrown toenails
- Once a diabetic has a partial or complete foot amputation, he or she is at high risk for further breakdown
- Rehabilitation of an BKA or AKA with a prosthetic in a diabetic can be extremely difficult
- Below knee and above knee amputations put significant stress on the heart and lungs

5

Impact of Ulcerations

“Foot ulceration is the most common single precursor to lower extremity amputations among persons with diabetes.”



JFAS, Diabetic Foot Disorders, Clinical Practice Guidelines

6

The Diabetic Foot

- More than 30 million Americans are living with diabetes, and more than 84 million US adults have prediabetes.
- More than 60% of leg and foot amputations not related to accidents and injuries are performed on people with diabetes.

November 14, 2018
Content source: [Centers for Disease Control and Prevention](#)

7

Diabetic Foot Statistics

- With appropriate therapy many DFUs will heal and avoid the need for some level of amputation
- Recurrence of DFUs in patients is common
 - 40% within 1 year
 - 60% within 3 years
 - 65% within 5 years

Armstrong et al, "Diabetic Foot Ulcers and Their Recurrence", NEJM, June 15, 2017, pp2367 - 2375

8

Diabetic Foot Statistics

5-Year Mortality Rates

Condition	5-Year Mortality Rate (%)
Prostate CA	8
Breast CA	18
Hodgkins	18
Neurologic Ulcer	45
Amputation	47
Colon CA	48
Ischemic Ulcer	55
PKD	64
Lung CA	86
Pancreatic CA	97

Armstrong DG, Wrobel J, Robbins JM. Guest Editorial: are diabetes-related wounds and amputations worse than cancer? *Int Wound J.* 2007;4(4):286-287

9

THE GOOD NEWS

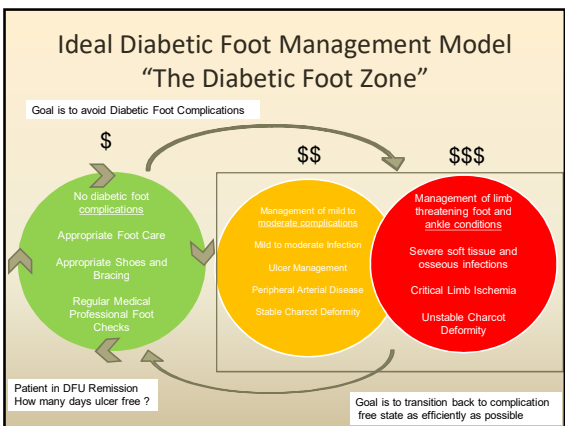
Diabetic Foot Problems are readily treatable and very preventable!

10

Realistic Diabetic Foot Care Model

- Recognize that diabetic foot issues range from the simple to the complex
- Need to be able to manage complex foot and ankle conditions in complex medical patients
- Recurrence of diabetic foot ulcers is common but not a sign of abject failure
- The high risk diabetic foot needs frequent monitoring

11



12

The Diabetic Foot Green Zone

- Patient Education
 - Foot-specific individualized patient education is the most important element of a comprehensive diabetic foot program.
- Prophylactic skin and nail care
 - Prevention of ingrown toenails and ulcers caused by thickened toenail
 - Prevent callus buildup
- Protective footwear
 - Protects feet from undo pressure and sheer forces
- Once a problem arises, the patient is instructed to seek medical attention immediately.
 - Dealing with problems early on is much easier

13

Palliative Care



14

Medical Care



15

Appropriate Callus Care


- Non-medicated Corn Pads
- Pumice Stone
- Moisturizing lotion
- Well fitting Shoes and Inserts
- Professional debridement
- Surgery to fix deformities



YES

16

Avoid Self Sharp Debridement



NO

17

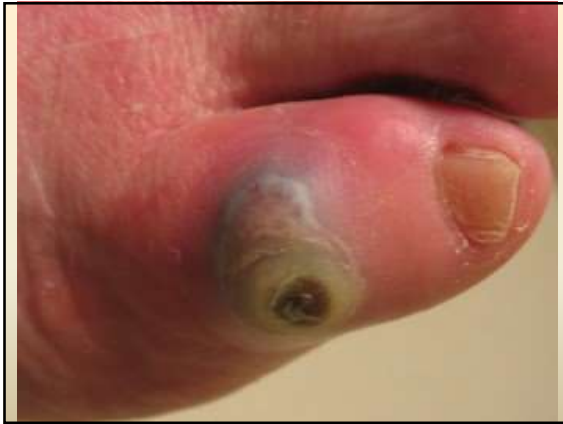Medicated Corn Pads



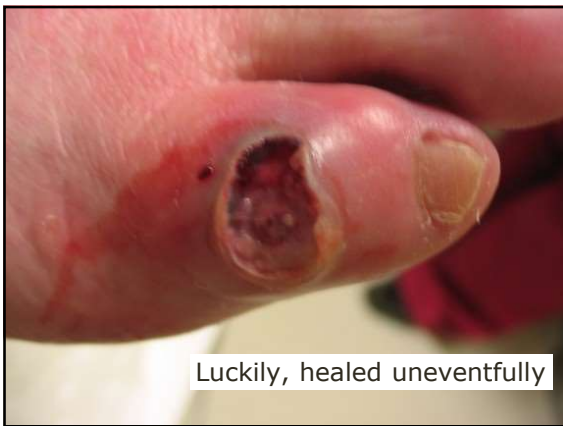NO



18



19




Luckily, healed uneventfully

20

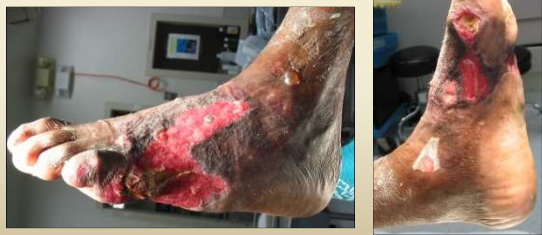Heating Pads and Diabetics Don't Mix

- Be Very Cautious!!!



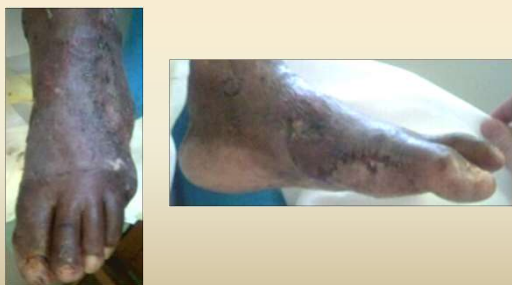21

Diabetic Male Fell Asleep with Heating Pad on his foot



22

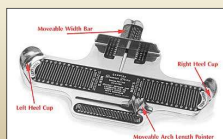
- Required multiple surgeries to save his foot.



23

Shoes and Inserts

- Very, very, very important.
- Different shoe brands ***do not*** have universal sizes
- Feet should be measured by a professional with the Brannock device
- Shoes and inserts should be replaced on an annual basis



24

Foot Care Study in Diabetic Patients

- Out of 23 male and female diabetic patients, **only 3** had shoes that were the correct size.
- Those 3 patients had been measured and fitted with diabetic shoes by a health professional

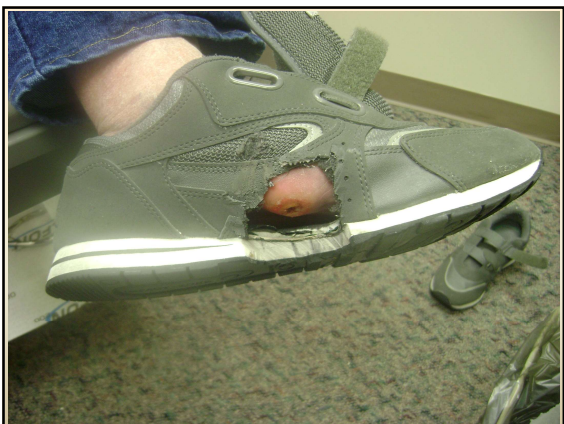Neil et al, Nephrology Nursing Journal, Feb 2003

25

- Accommodative inserts and shoes should be dispensed by a professional
- Shoes and inserts protect feet from high pressures and shearing forces
- Accommodate foot deformities




26



27

Keys to Prevention in the Green Zone

- Education
- Checking Feet Daily
- Cleaning feet daily
- Moisturizing Feet Daily
- Care for nails and calluses in a safe appropriate manner. If you cannot take care of them, see a health care professional on a regular basis
- Report ANY changes, even if it seems minor, to your doctor immediately
- Wear appropriate size shoes and accommodative inserts or bracing as needed



28

The Diabetic Foot

• **Yellow Zone** **Red Zone Management**

- Requires more advanced care
- May require hospital inpatient management
- May require surgical intervention
- If condition worsens, patient becomes more at risk for needing a more proximal leg amputation

29

The Diabetic Foot
Yellow Zone Management

Management of mild to moderate diabetic foot and ankle complications

- Mild to moderate Infection
- Ulcer Management
- Peripheral Arterial Disease
- Stable Charcot Deformity
- Foot and ankle deformity

30

**The Diabetic Foot
Red Zone Management**

- Management of limb threatening foot and ankle conditions
- Severe soft tissue and osseous infections
- Critical Limb Ischemia
- Unstable Charcot Deformity
- Foot and Ankle Deformity

31


Charcot Foot and Ankle Definition

“Charcot foot is a progressive condition characterized by joint dislocation, pathological fractures, and severe destruction of the pedal architecture.”

JFAS, Supplement 2000, Diabetic Foot Disorders: A Clinical Practice Guideline, p S39

Complex foot and ankle trauma in complex patients.

Depending on individual case:
Surgical or non surgical care



32

Diagnosis

- History
 - Neuropathy – known or unknown by patient
 - Trauma – common but may not be realized by patient
- Clinical
 - Red, hot swollen foot
 - Pain is typically minor for the amount of injury
- Imaging
 - Radiographs are typically all that is needed
 - MRI – can be useful in early stages for increased inflammation
 - CT and bone scan

33

AO Principles for Foot and Ankle Trauma

- Accurate anatomical reduction
- Rigid internal compression fixation
- Atraumatic surgical technique
- Early pain free mobilization

- **Difficult to adhere to these principles with surgical Charcot management**

34


Treatment of Charcot Deformity

- Treatment is “reactive”
- Do not have the ability to screen or predict who or when a charcot event will occur
- ***The goal of treatment whether it be surgical or non-surgical is to achieve a stable and plantigrade foot that enables functional ambulation with footwear and bracing or a stable limb for transfers.***

35

When to perform Surgery ?

- Historically conservative care was instituted in acute stages and surgery was considered only during the quiescent stages
- Currently, much controversy exists about performing surgery earlier to stabilize more acute stages of Charcot arthropathy



36

Common Reasons to Operate in the Literature

- Recalcitrant ulcers despite appropriate offloading trial
- Acute fractures and dislocations in the hindfoot and ankle
- Unstable and painful foot and ankle deformity
- Resecting infected bone in cases of osteomyelitis
- Achilles tendon lengthening to mitigate midfoot forces

Rogers et al, "The Charcot Foot in Diabetes" *Diabetes Care*, Vol 34, September 2011, 2123- 2129

37

Surgical Treatment

- In general, perform more simple procedures to more complex
- Correction of equinus deformity
- Exostectomies - **not typical for hindfoot and ankle**
 - When foot is structurally stable and bony prominence is underlying etiology
- Arthrodesis and Osteotomy procedures
 - When architecture of foot and ankle is not structurally stable

38

Roger's Charcot foot classification system

- Based on location and stage
- Location
 - Forefoot to Rearfoot/Ankle
- Stage
 - Charcot with and without deformity
 - Charcot deformity with ulcer
 - Charcot deformity with osteomyelitis

Predictor of Extremity amputation


Location and Stage	(more proximal)
	1. Forefoot 2. Midfoot 3. Rearfoot/Ankle
A. Acute Charcot without deformity	Low Risk of Extremity Amputation
B. Charcot with deformity	
C. Charcot with deformity and ulceration	
D. Charcot with osteomyelitis	High Risk of Extremity Amputation

(more complicated) ↓

Rogers LC, Bevilacqua NJ. The diagnosis of Charcot foot. *Clinics in Podiatric Medicine and Surgery*, 2008;25: 43-51

39

Diabetic Ulcer Management





1. Vascular Supply
2. Debridement
3. Infection
4. Offloading and Deformity Correction
5. Wound Management
6. Wound Closure
7. Management of medical comorbidities

40

Vascular

History and Physical Exam





- Intermittent Claudication
- Rest Pain
- Gangrene
- Palpable Pulses
- Cold extremity
- Dependent Rubor
- Absent hair growth
- Capillary Refill Time
- Gangrene



41



Non-invasive Vascular Exams

- Doppler Ultrasound
- Segmental Blood Pressure
- Ankle Brachial Index
- Toe Blood Pressure
- Plethysmography
- Transcutaneous Oxygen Pressure



42



Need to be prudent with vascular intervention if warranted

Endovascular	Surgical
	

43

Wound debridement

- Must remove necrotic tissue to expose healthy tissue
- Reduce bacterial burden
- 4 basic types of debridement :
 - autolytic
 - enzymatic
 - biotherapy
 - mechanical

44


Clinical Guidelines for Treatment of Diabetic Foot Infections

IDSA GUIDELINES

2012 Infectious Diseases Society of America Clinical Practice Guideline for the Diagnosis and Treatment of Diabetic Foot Infections¹

Benjamin A. Lipsky,¹ Anthony B. Herzig,² Paul B. Ginn,³ James C. Pihl,⁴ Edgar J. S. Probst,⁵ David G. Armstrong,⁶ H. Gerson Dancy,⁷ John M. Eide,⁸ Warren S. Joseph,⁹ Abdul W. Kulkarni,¹⁰ Michael S. Paine,¹¹ and D. S. Senanayake¹²

¹Department of Medicine, University of Pittsburgh Medical Center, Veterans Affairs Medical Center, Pittsburgh, Pennsylvania; ²Department of Medicine, University of Pittsburgh Medical Center, Pittsburgh, Pennsylvania; ³Department of Medicine, University of Pittsburgh Medical Center, Pittsburgh, Pennsylvania; ⁴Department of Medicine, University of Pittsburgh Medical Center, Pittsburgh, Pennsylvania; ⁵Department of Medicine, University of Pittsburgh Medical Center, Pittsburgh, Pennsylvania; ⁶Department of Medicine, University of Pittsburgh Medical Center, Pittsburgh, Pennsylvania; ⁷Department of Medicine, University of Pittsburgh Medical Center, Pittsburgh, Pennsylvania; ⁸Department of Medicine, University of Pittsburgh Medical Center, Pittsburgh, Pennsylvania; ⁹Department of Medicine, University of Pittsburgh Medical Center, Pittsburgh, Pennsylvania; ¹⁰Department of Medicine, University of Pittsburgh Medical Center, Pittsburgh, Pennsylvania; ¹¹Department of Medicine, University of Pittsburgh Medical Center, Pittsburgh, Pennsylvania; ¹²Department of Medicine, University of Pittsburgh Medical Center, Pittsburgh, Pennsylvania



IWGDF Guidance on the diagnosis, prognosis and management of peripheral artery disease in patients with foot ulcers in diabetes
 Prepared by the IWGDF Working Group on Peripheral Artery Disease

45

Diabetic Foot Infections

Cultures

- Swab – try to avoid swabs if possible
 - Should not be superficial culture of ulcer base
 - Should be deep swab
 - Collection of purulence
- Deep tissue
 - Best indication is deep tissue culture
- Bone
 - If suspected, bone biopsy for culture and histology

46

Treatment of Diabetic Foot Infections

General Treatment

- Eradicate bacterial load with incision and drainage and debridement
 - This step must be done regardless of vascular supply
 - **Must remove ALL Non-Viable Bone and Soft tissue. Worry about closure of wound when infection eradicated.**
- Start with empirical antibiotics and focus therapy based on reliable deep cultures
 - Length of antibiotics depends on severity of infection, response of infection to treatment (typically 2 to 8 weeks)
 - Oral
 - Intravenous
 - In-patient
 - Out-patient (PICC line, Central line)
 - Antibiotic beads
- Closure of wounds

47

External Off loading



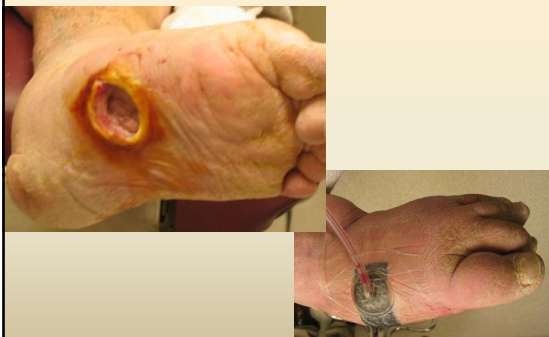48

Wound Management

- 1000's of different wound care products
- Many skin substitute grafts
- Daunting task
- My approach
 - If it is wet keep dry and if it is dry make it wet
 - Economical for the patient
 - Have an ultimate plan for closure of the wound and update patient often on progress and need for change if wound stalls

49

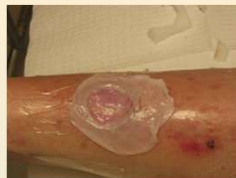Negative Pressure Wound Therapy



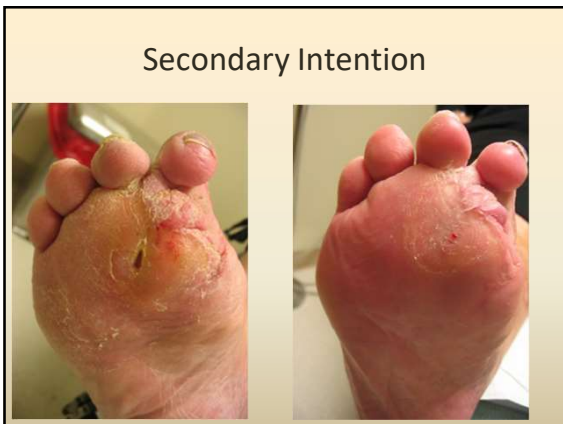50

Skin Equivalents

Many options now available




51



52

How to Approach ?

- Vascular supply is optimized
- Infection Controlled
- Wound debrided
- Good wound management
- Foot offloaded but not healing due to complex foot deformity ?



53

Orthoplastics Definition

“The principles and practice of both orthopedic and plastic surgery applied to a clinical problem either by a single provider or team of providers working in concert for the benefit of the patient.” L. Scott Levin, MD

L. Scott Levin, "The Reconstructive Ladder: An Orthoplastic Approach" Orthopedic Clinics of North America, July 1993, pp393 - 409


Oren Lerman, et al "The Respective Roles of Plastic and Orthopedic Surgery in Limb Salvage" Plastic and Reconstructive Surgery, January Supplement 2011, pp215S - 227S

54

Orthoplastics and the Diabetic Foot Ulcer

- Makes sense to concomitantly manage the soft tissue and musculoskeletal deficiencies

Soft Tissue Reconstructive Ladder




Musculoskeletal Reconstructive Ladder

55

My Approach to the Soft Tissue Reconstructive Ladder

1. Secondary Intention
 - Skin Equivalent Grafts
 - Topical Growth Factors
 - Negative Pressure Wound Therapy
2. Primary Closure
3. Split thickness or full thickness skin graft
4. Local random flaps
 - Rotational, V to Y, Translational
5. Regional axial flaps
 - Lateral calcaneal artery, medial plantar artery, intrinsic muscle foot, Perforator
6. Distant axial flaps
 - Reverse sural artery flap, peroneus brevis, hemiseleus muscle flaps



*Hyperbaric Oxygen Therapy – adjunctive treatment when indicated during all phases of the reconstructive ladder

56

Musculoskeletal Reconstructive Ladder

- System to guide treatment of musculoskeletal factors impeding the healing of diabetic foot ulcers.
- Need to consider:
 - Bone
 - Joint
 - Tendon and ligament
- Treatment can range from the simple to complex and can involve only one component or any combination of the foot and ankle musculoskeletal system

57

Musculoskeletal Reconstructive Ladder

Common musculoskeletal conditions impeding diabetic foot ulcer healing

- Prominent bone
- Bone deformity
- Osteomyelitis
- Joint deformity
- Joint contracture
- Joint instability
- Septic Joint
- Tendon and ligament imbalance

58

Musculoskeletal Reconstructive Ladder

Bone

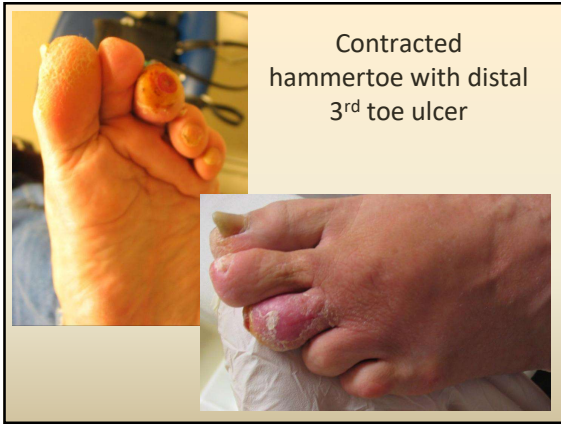1. Simple ostectomy
2. Resection
 1. Partial
 2. Complete
3. Osteotomy
4. Bone grafting
5. Bone transport

59

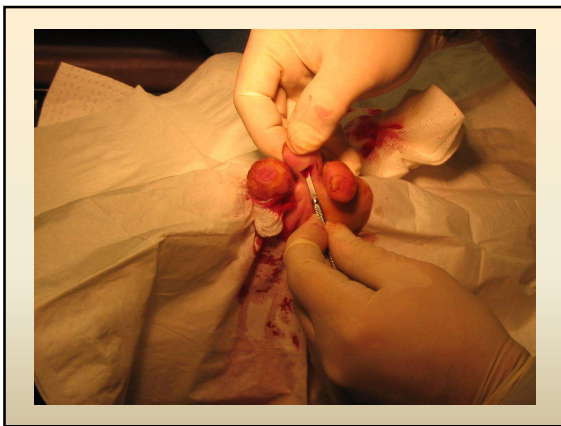
The Diabetic Foot Yellow Zone Management

Case Examples

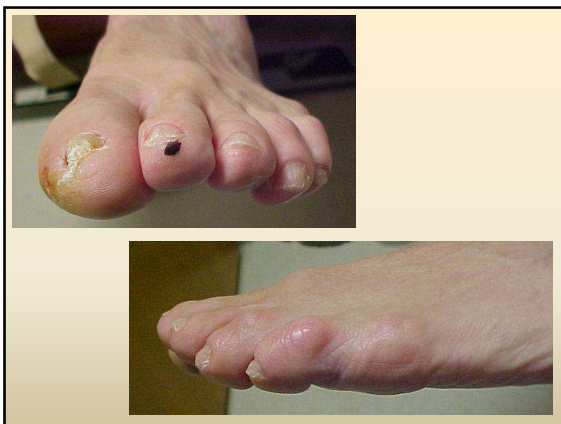60



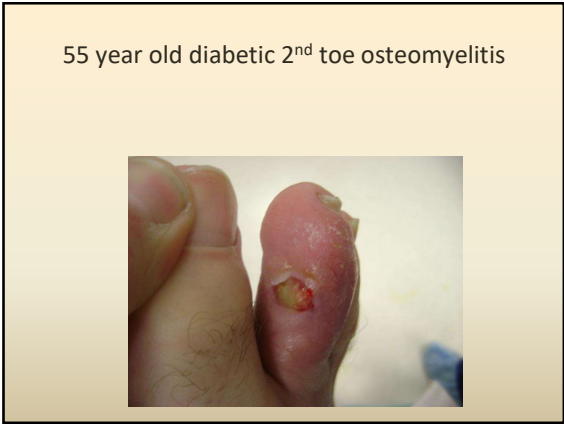
61



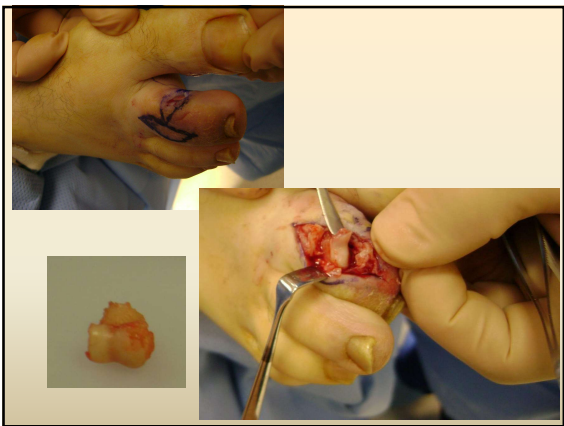
62



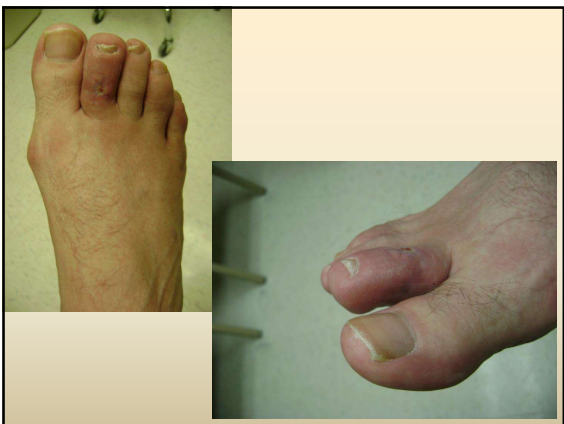63



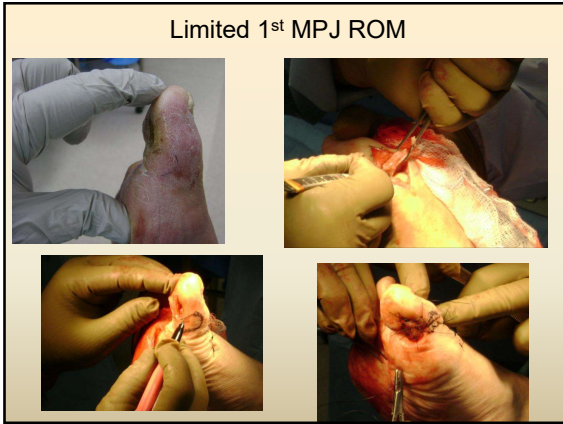
64



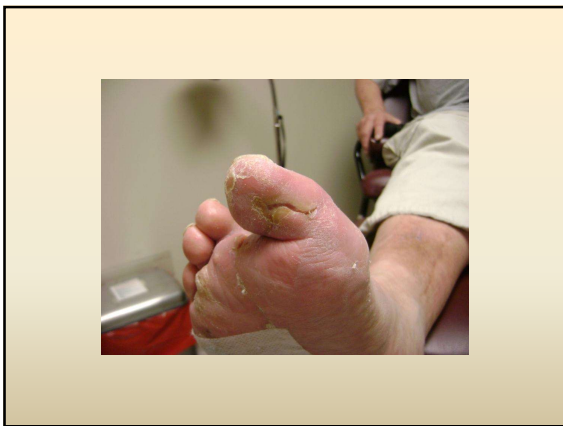65



66



67

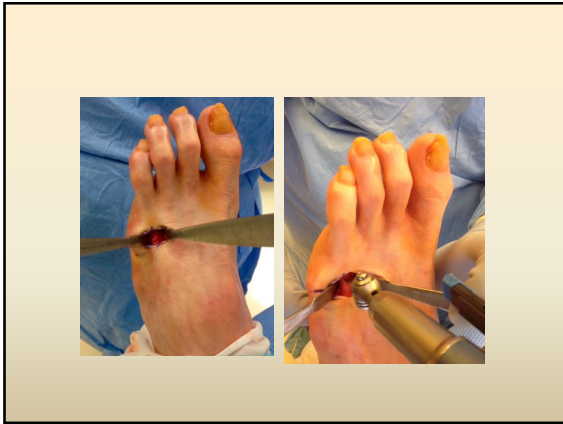

68

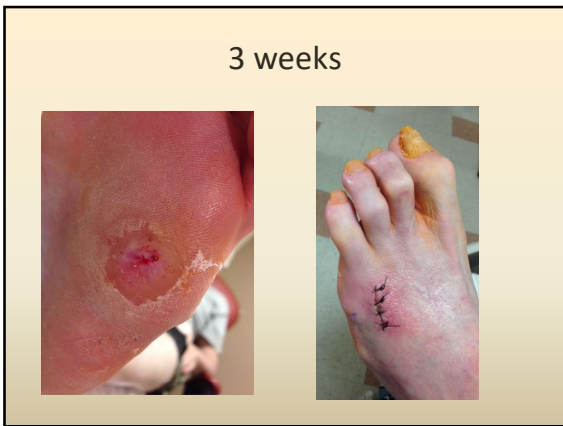56 year old Type II diabetic Male

- 5th ray resection
- Transfer ulcer to the 4th metatarsal head
- Present for over 3 months despite comprehensive wound management and offloading
- No signs of deep bone infection

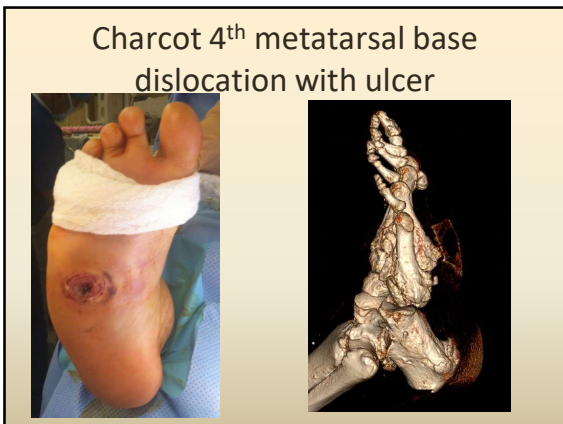
69



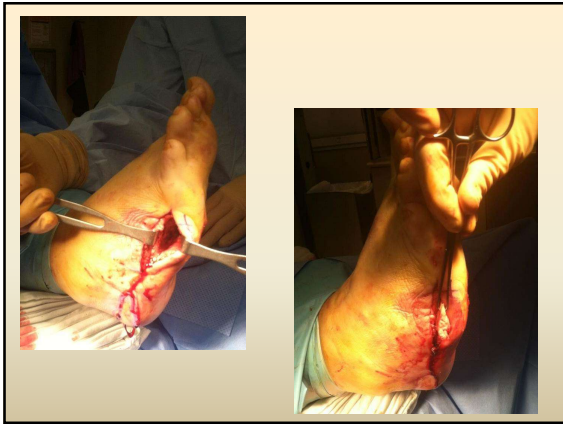70



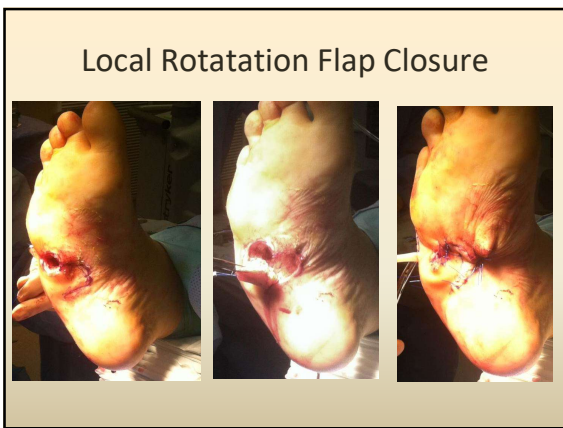
71



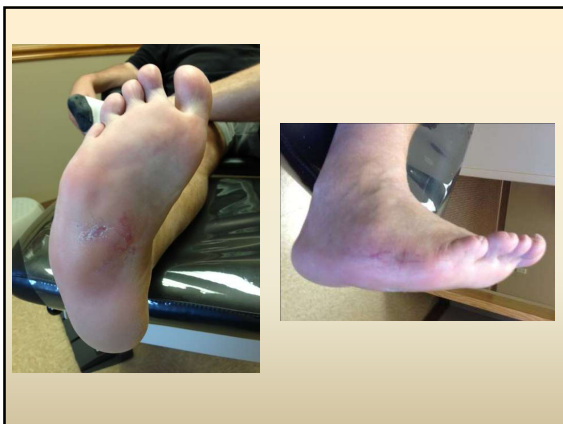72



73



74



75

**The Diabetic Foot
Red Zone Management**

Case Examples

76

40 year old diabetic male with a wound in his 1st interspace

- 5 day history of swelling, drainage and erythema in the 1st innerspace after stepping on a roofing nail at work
- Worsening symptoms of malaise and pain in forefoot
- WBC -17.00
- Temp – 100 F
- Xrays – negative for gas or bone destruction




77

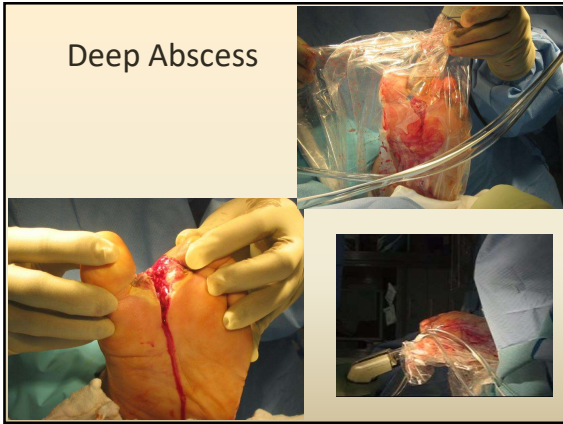Limb Threatening Deep Abscess

Treatment

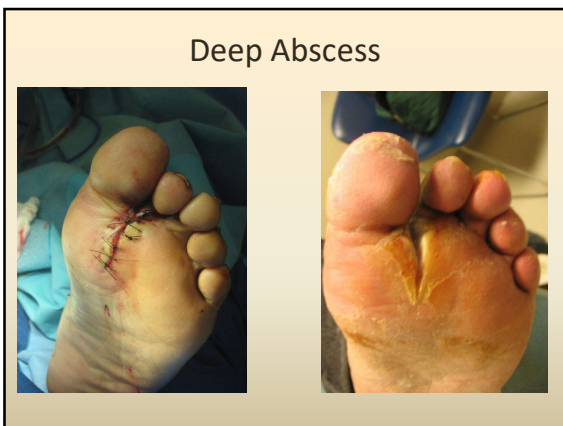- Admitted to hospital
- IV Unasyn
- I&D performed that day
- Deep cultures taken
- 2 weeks of IV antibiotics



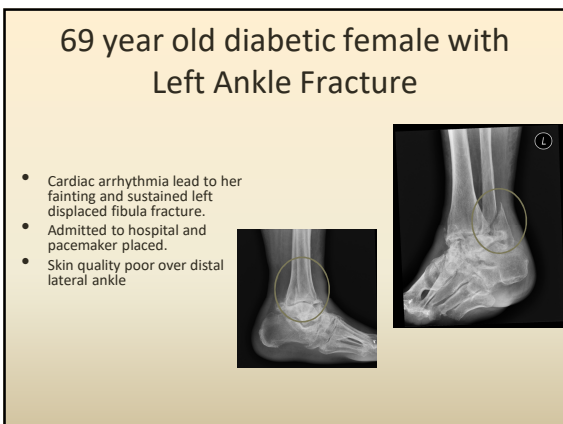78



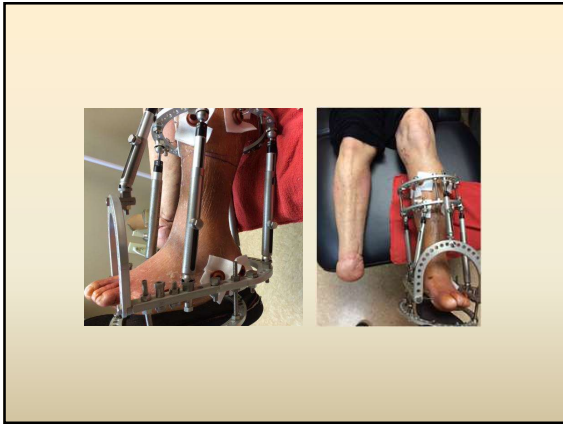79



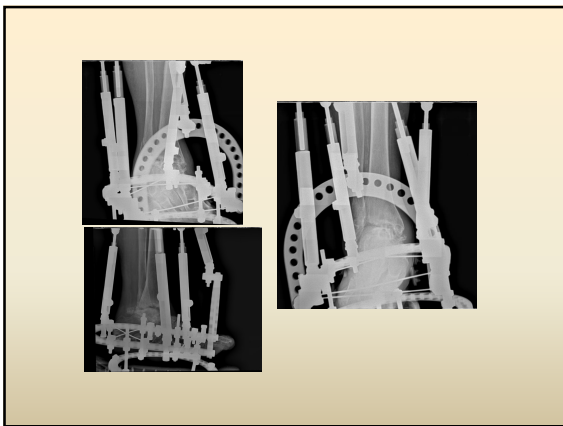
80



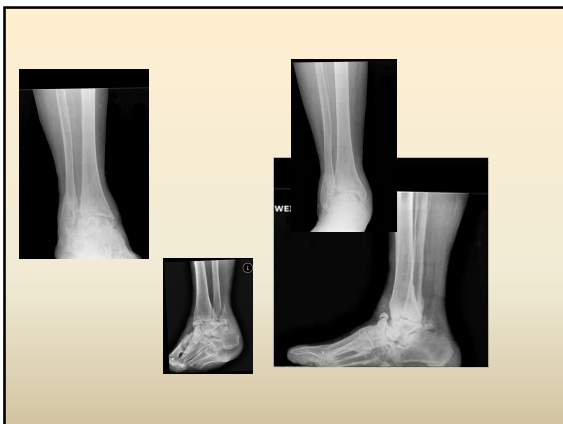81



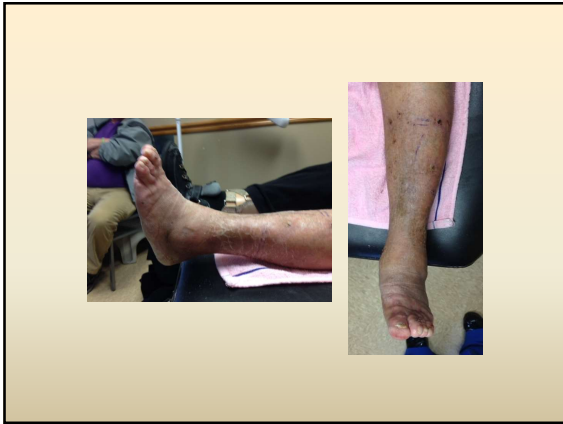82



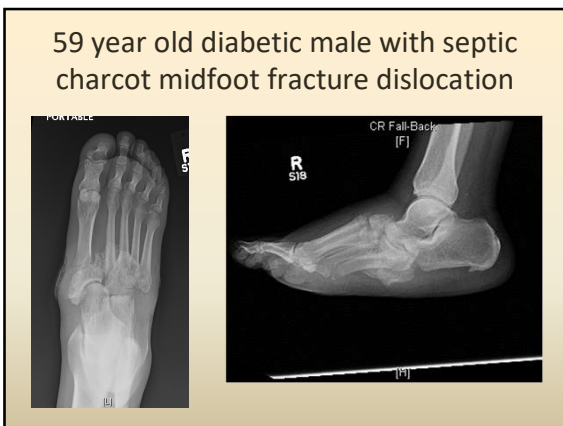
83



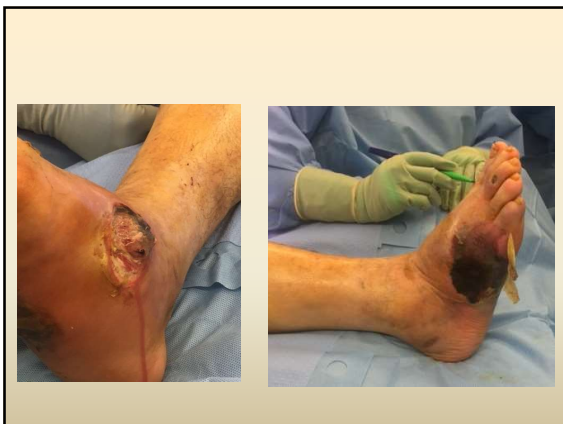84



85



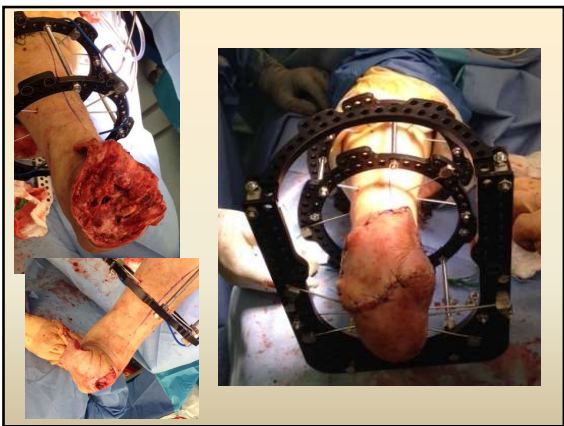
86



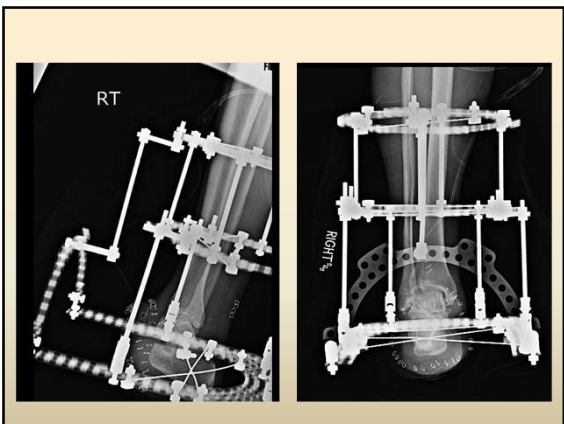
87

- Required radical resection of the midfoot
- Subsequently, even though with Charcot deformity required LE arterial endarectomy to optimize blood flow
- IV antibiotics
- Choparts amputation with subtalar joint and ankle fusion

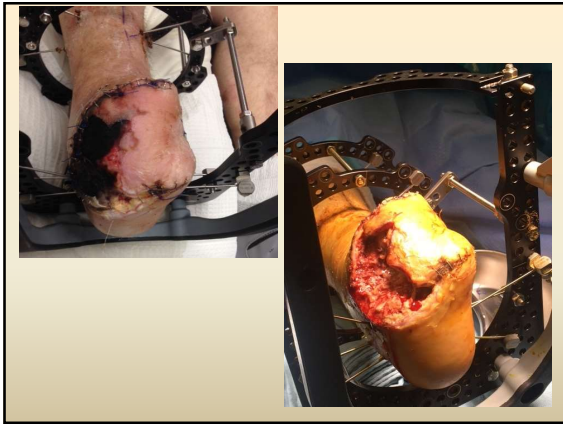88



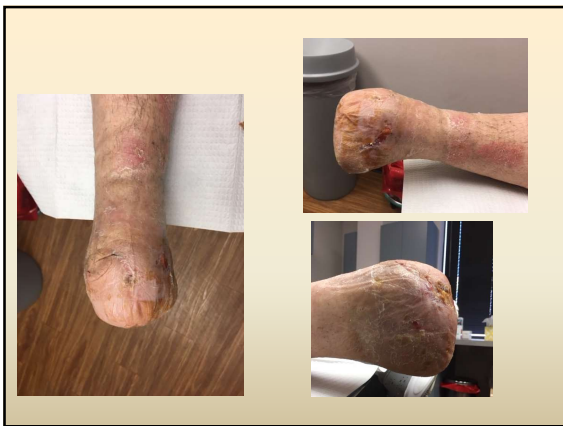89



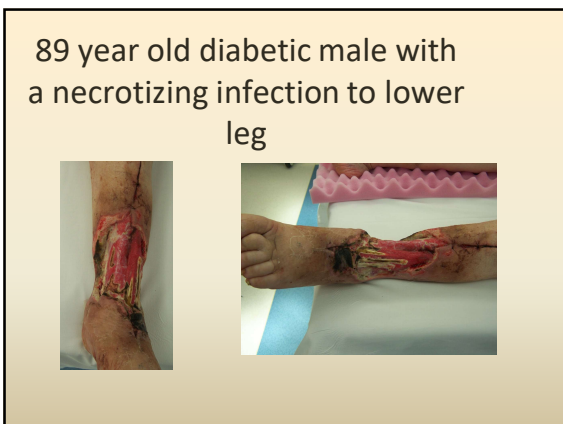90



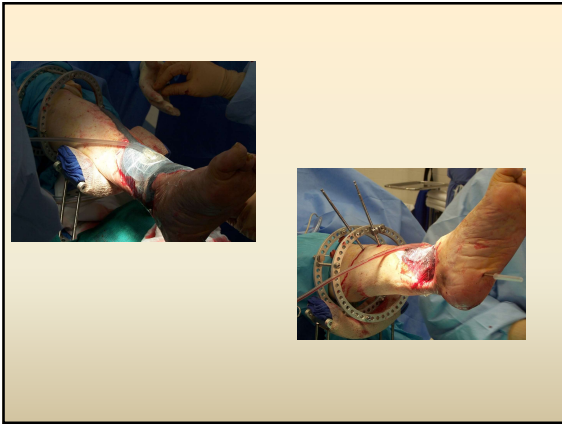
91



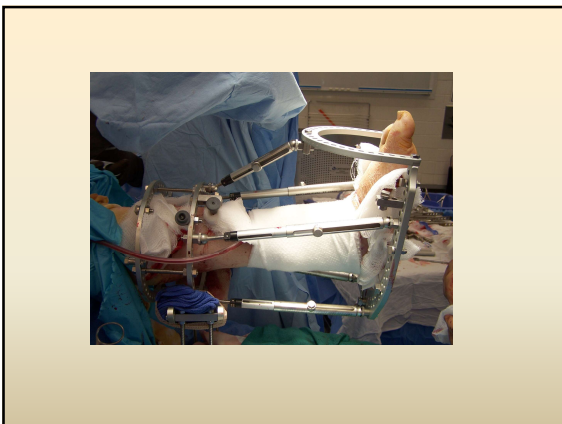
92



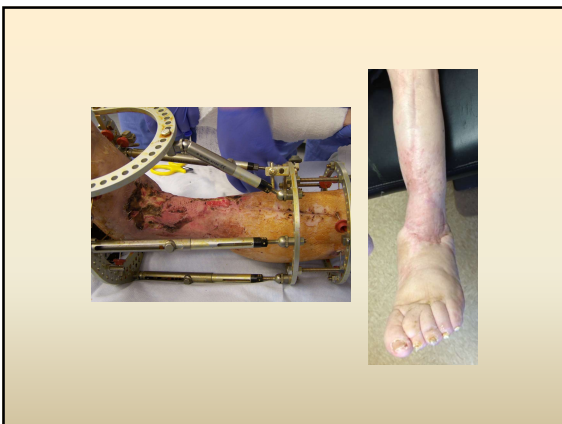93



94



95

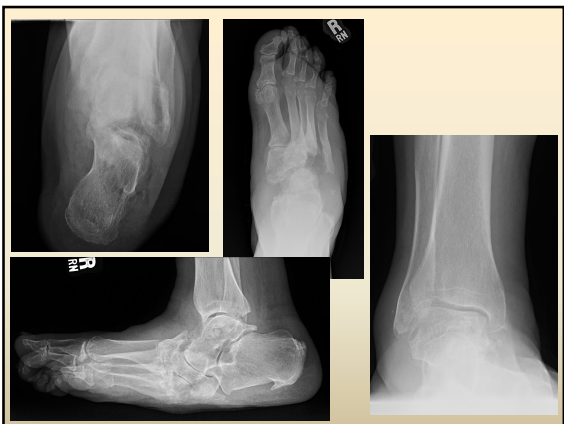

96

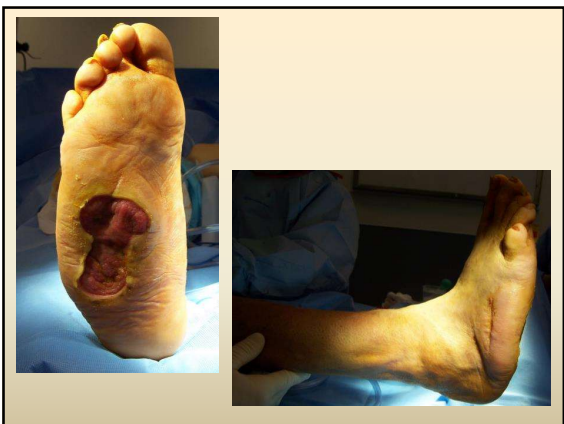50 year old diabetic male with charcot rockerbottom deformity

- Treated with multiple surgical debridements of the lateral plantar cuboid and 5th ray for infections.
- Lead to PB dysfunction and complex rockerbottom and varus deformity
- Non-healing wound despite aggressive wound care and non-surgical offloading

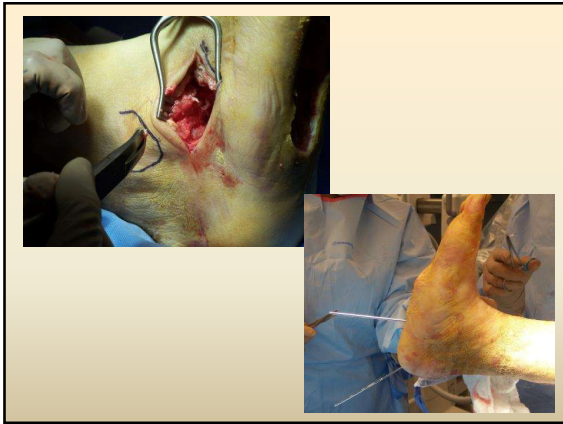97



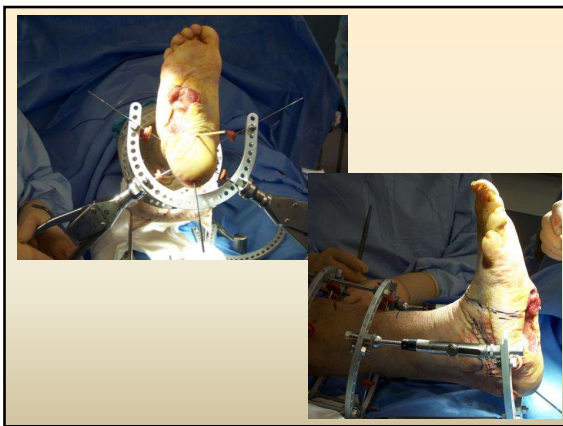
98



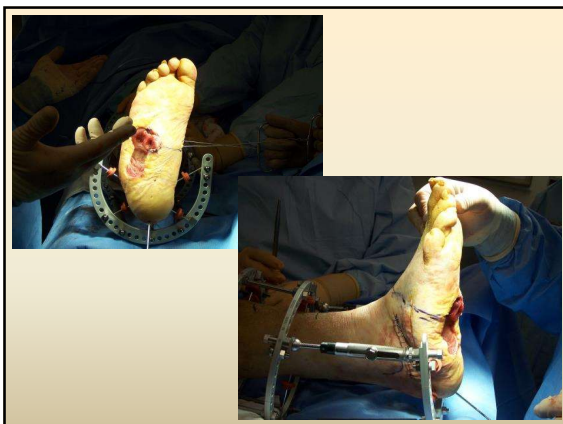
99




100



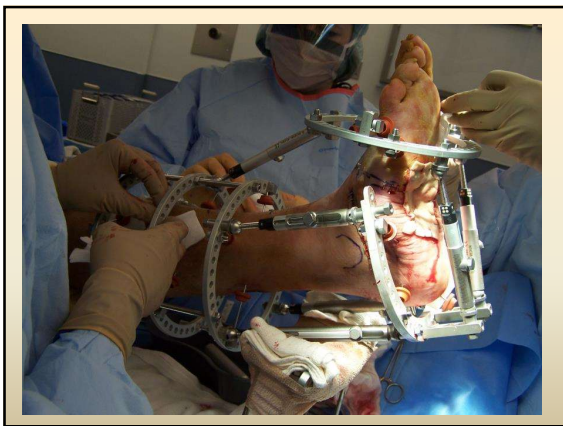
101



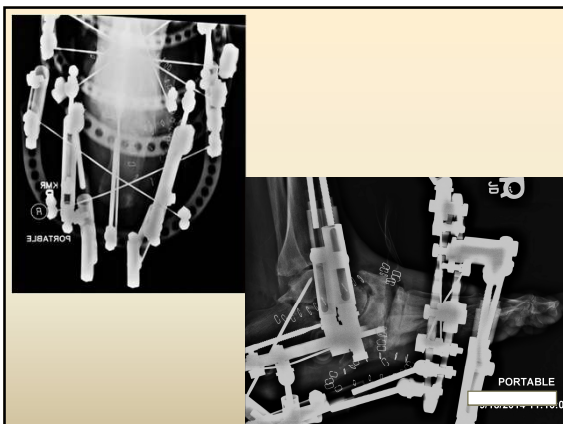
102



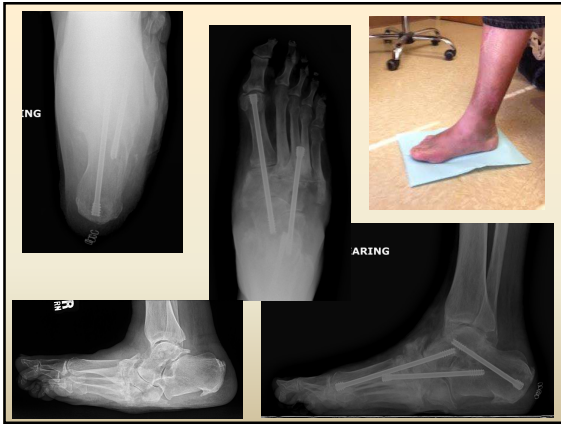103



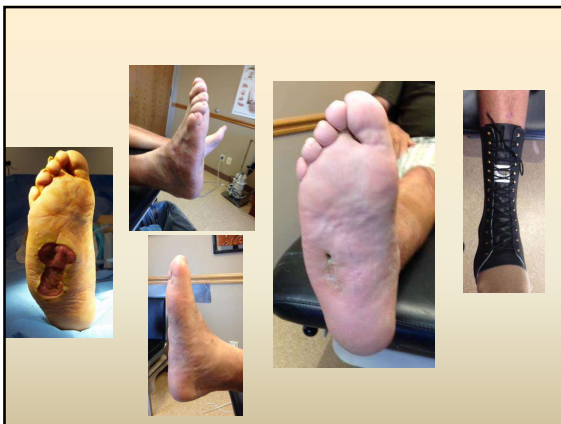104



105



106

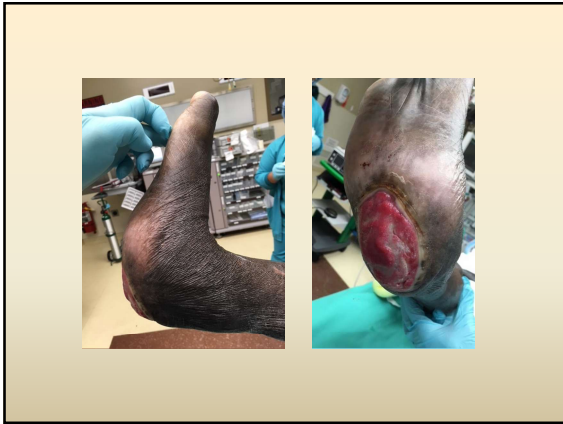

107

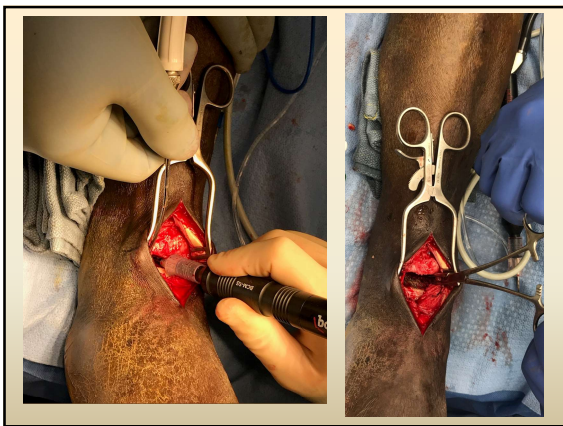
60 year old ESRD diabetic male with heel ulcer

- Multiple debridements
- Friable granulation tissue with bone exposed
- Full resection of the achilles tendon leading to unstable hindfoot and ankle with calcaneal gait

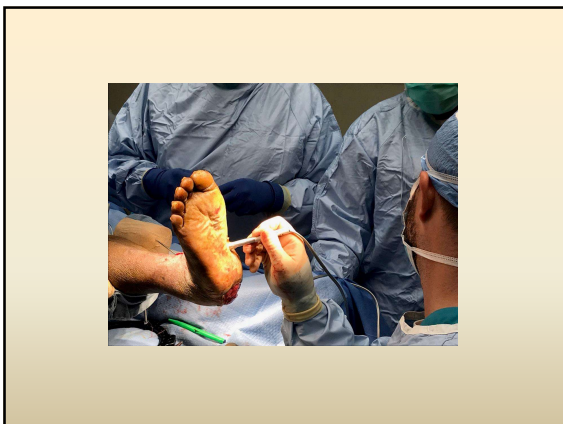
108



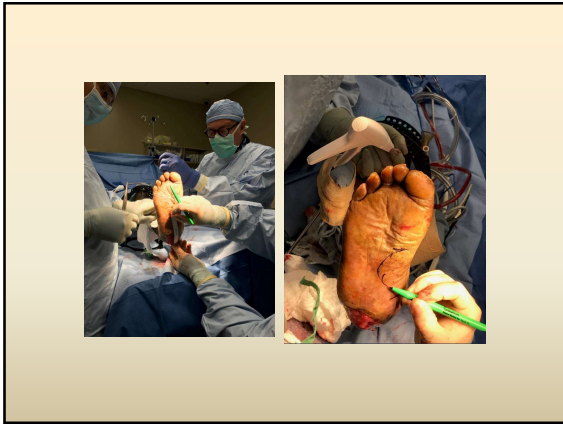
109



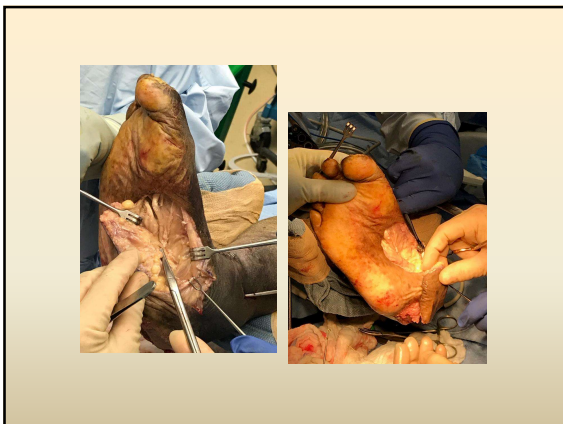110



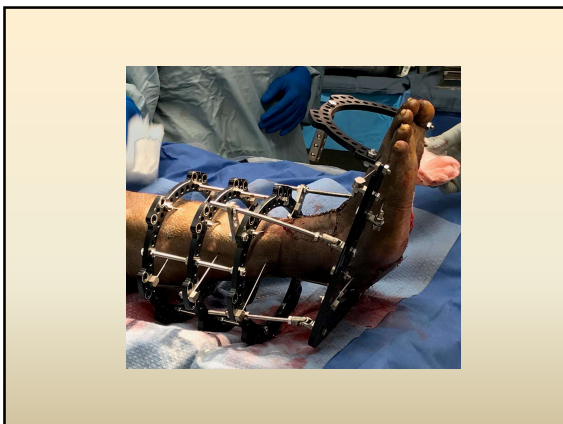
111



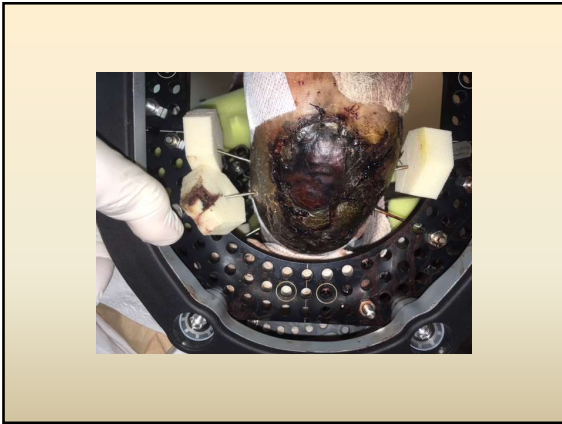
112



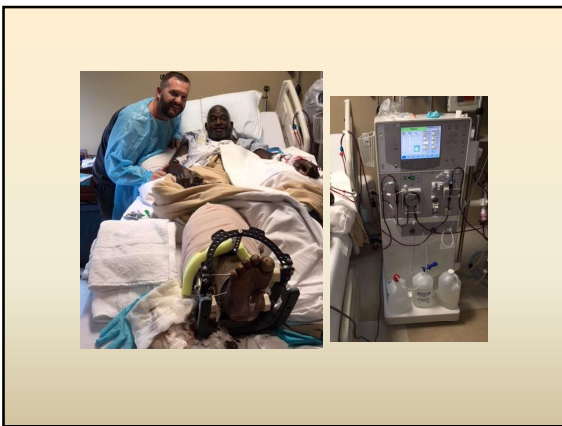
113



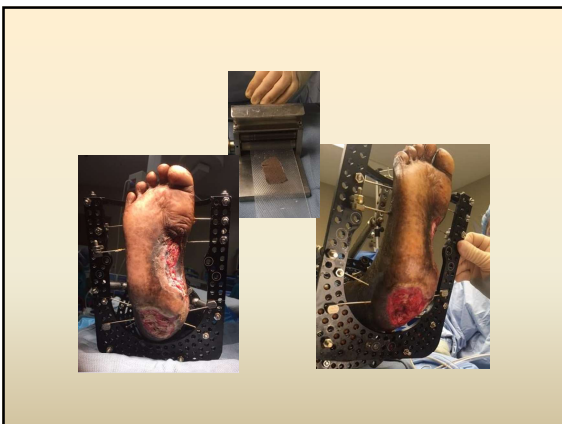114



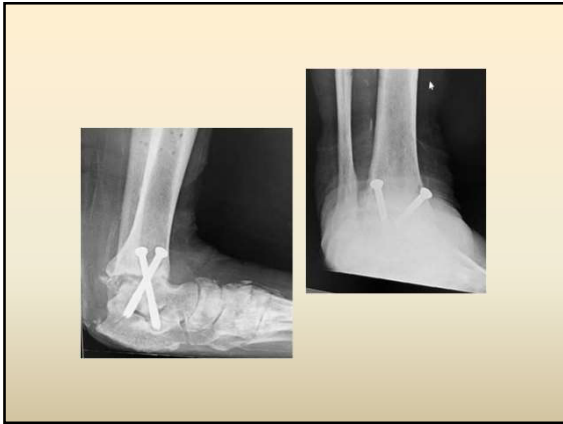115



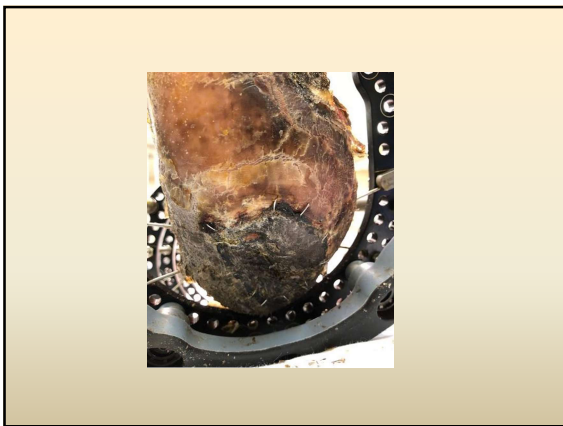
116



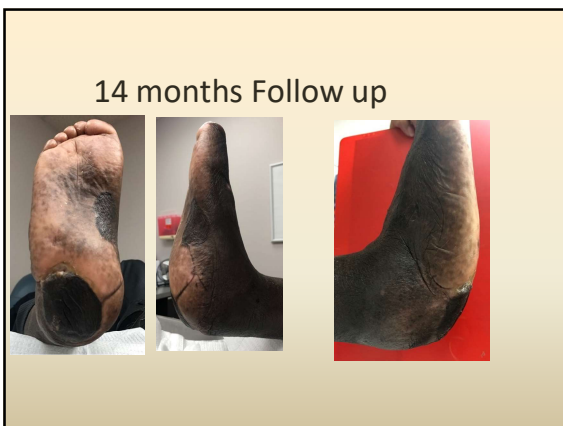117



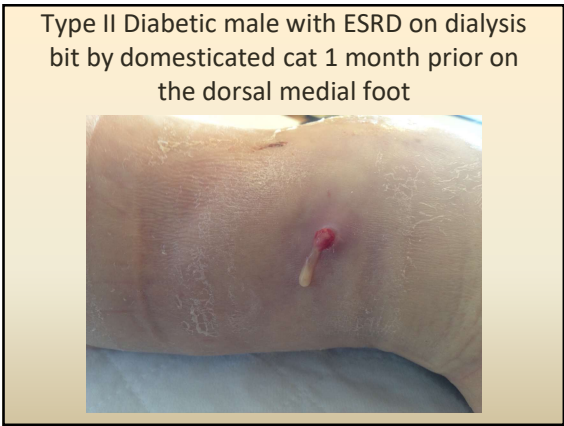118



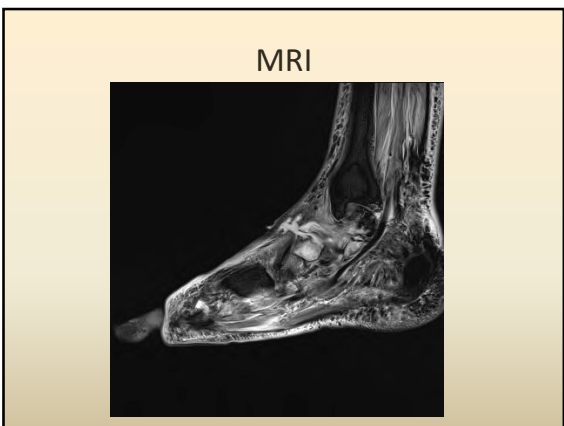
119



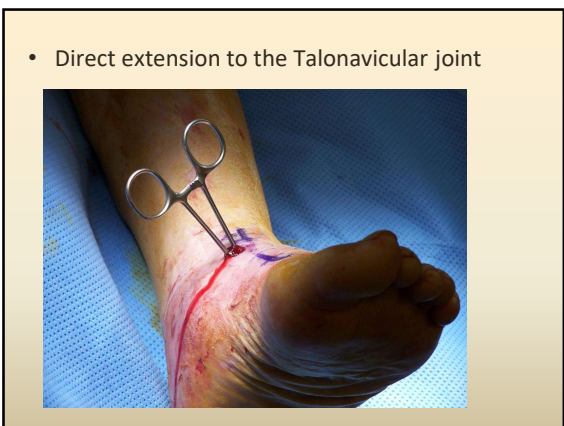
120



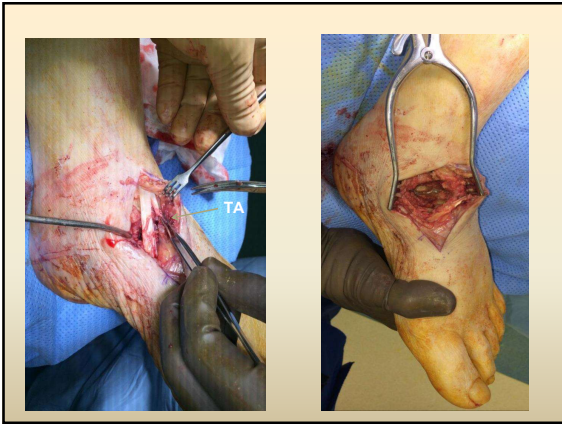
121



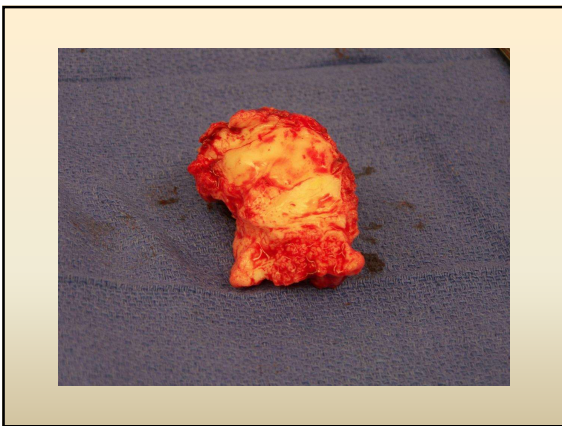122



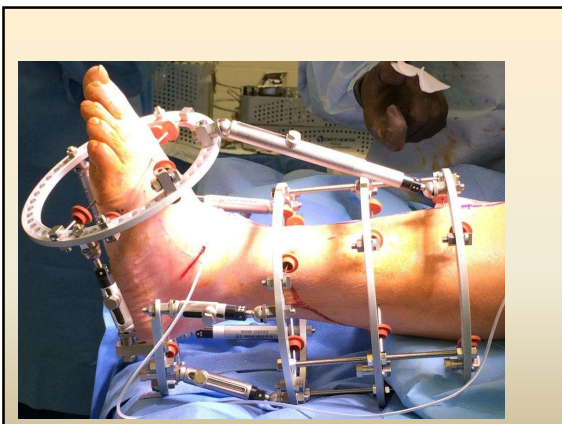
123




124



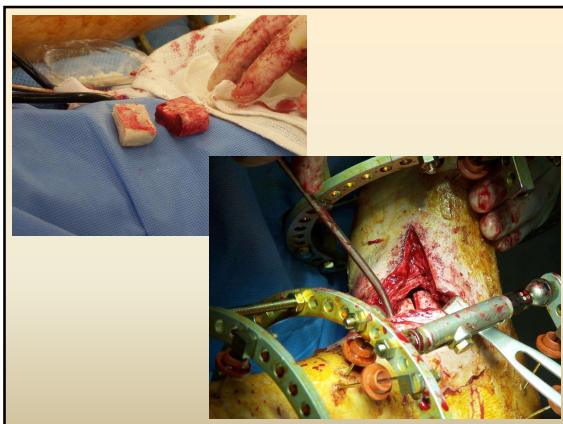
125



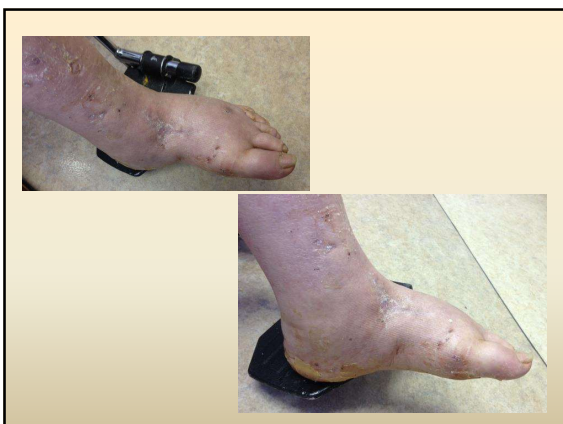126



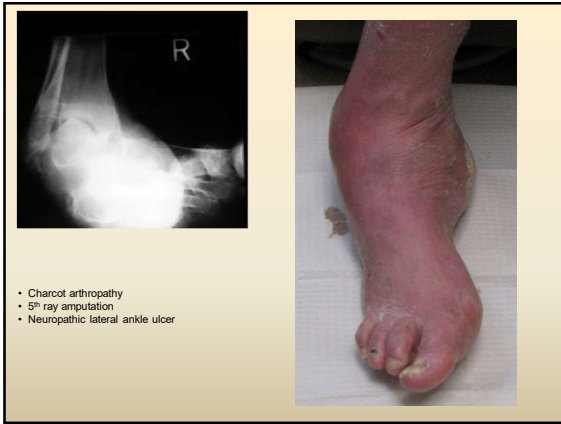127



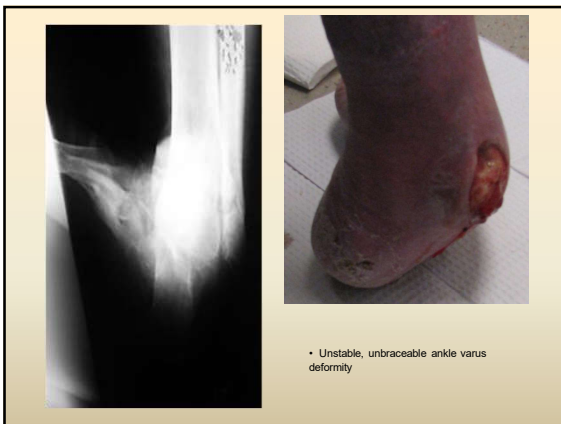128



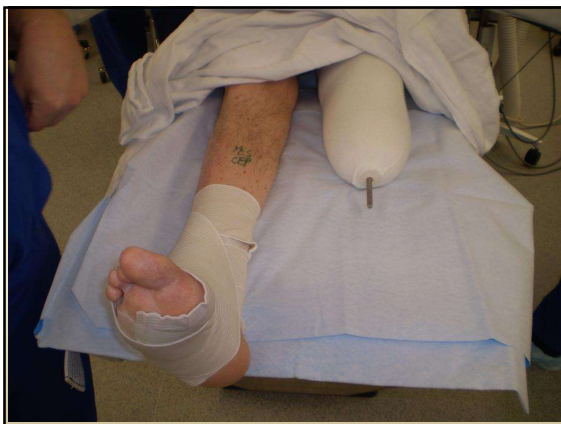129



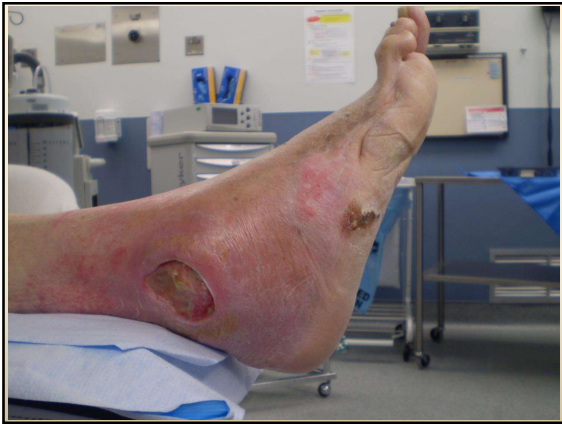130



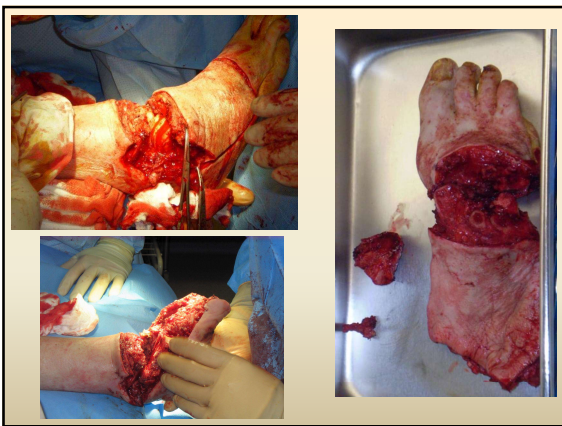
131



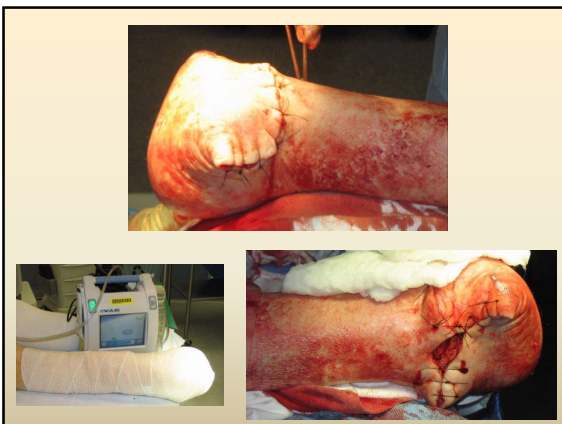132



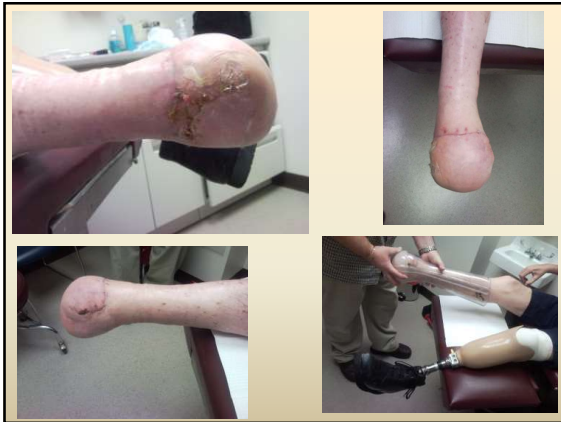133



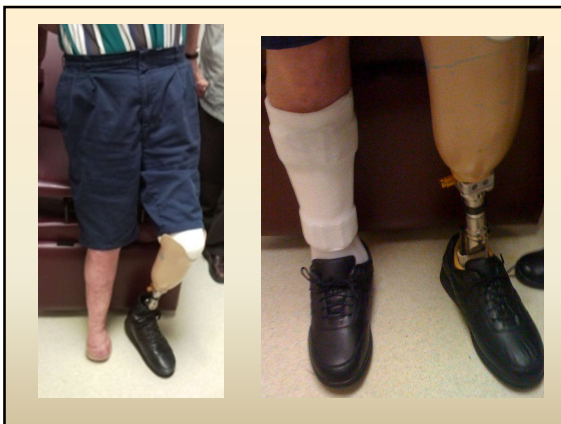134



135



136

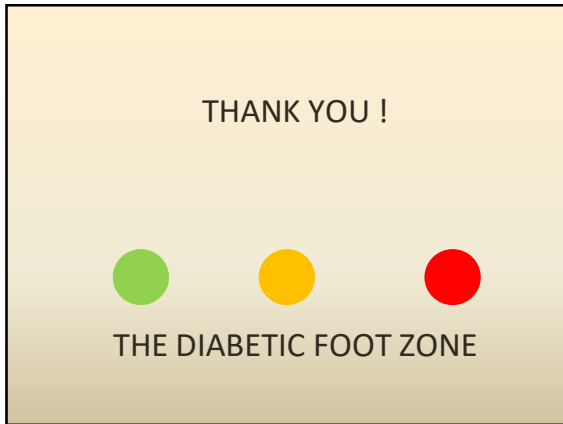

137

Conclusion

- The Diabetic Foot can require simple to complex management
- Contemporary trend is to approach diabetic foot complications similar to a comprehensive cancer treatment model
- Diabetic foot complications are serious and have potential for significant morbidity and mortality for patients
- Treatment requires a team approach and much needs to be done to improve outcomes for patients

138



139